



Milled Bar Overdentures-Protocol and Procedures

Dennis Urban, CDT

When full implant dentures requiring a milled bar is prescribed, the proper protocol and procedure are of extreme importance. The proper impression, bite registration, verification index, denture tooth set-up, internal framework and bar design are of the utmost importance. There are too many instances where the doctor wants to take a shortcut by eliminating the verification index or the set-up. Both of these procedures are a must for a successful overdenture case.

In addition, always recommend an internal metal framework for support of the attachments to increase the strength

of the overdenture. Most of the time when a framework is not incorporated into the overdenture, breakage will occur. Where does it occur? In the weakest area not supported by metal and acrylic: the attachment areas.

How many times have you had an instance where the Denturist has asked you to eliminate the metal framework just to save money? The result, a few weeks later the case is back in the laboratory for repair and will continue to come back until an embedded frame is placed in for support.

The following case was sent to the lab to

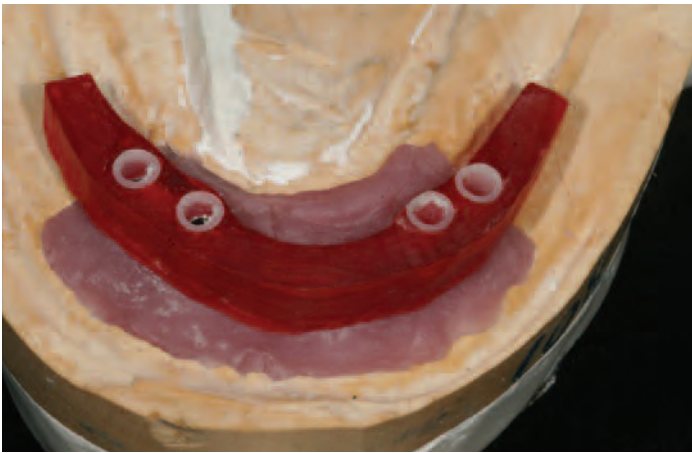


Figure 1 — Verification Index in Pattern Resin

be finished after the models and bite registration were completed by another laboratory. A verification index was previously made (Fig. 1) and the Denturist was sure the impression and model work was accurate.

The first step was to do a denture set-up to check the patient’s occlusion so we could get an idea of how much room was available for a milled bar .

After the case consult it was decided that the best direction to take was to make a milled bar utilizing Rhein 83’s OT Equator attachments. We had completed numerous cases in the past with Equator attachments with complete success and this case was the perfect case for Equator attachments.

The OT Equator has the lowest profile (Figs. 2 and 3) and smallest diameter available of 4.4 mm as well as a vertical height of 2.1 mm. It is compatible with all implant brands with cuff heights from 4.4mm to 7mm and includes multiple levels of retentive caps, which are retained by steel housings.

OT Equator abutments are available in



Figure 2 — Equator retentive caps with housing

OT EQUATOR

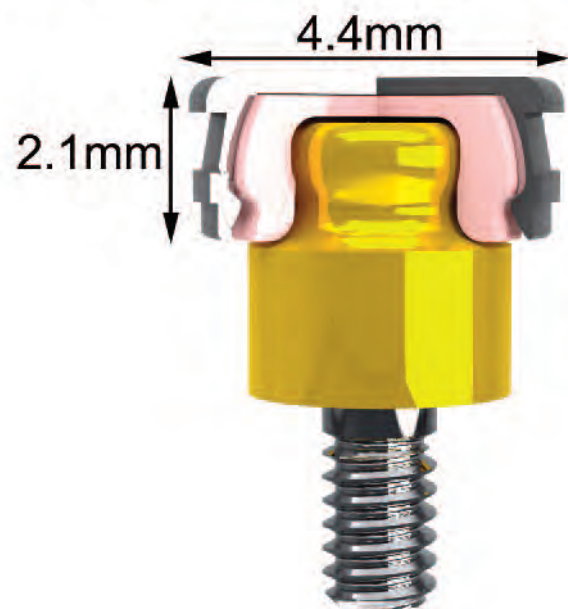


Figure 3 — Rhein 83 OT Equator



Figure 4 — Set up for try-in

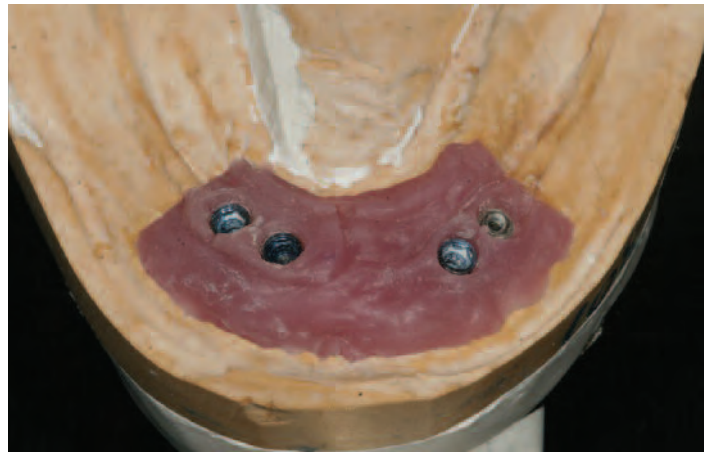


Figure 5 — Implants

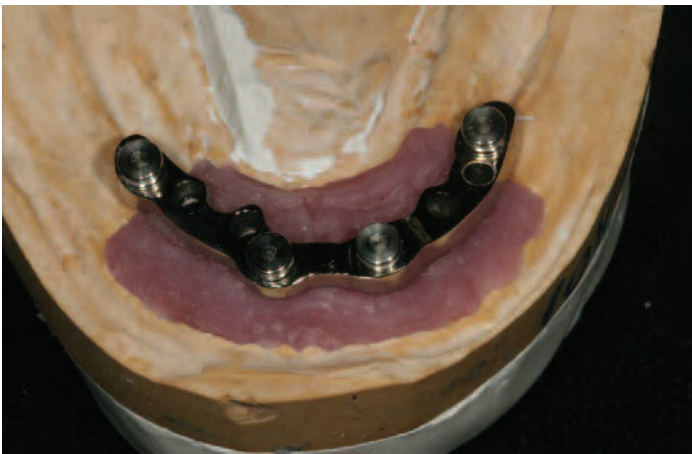

Figure 6 — Finished milled bar

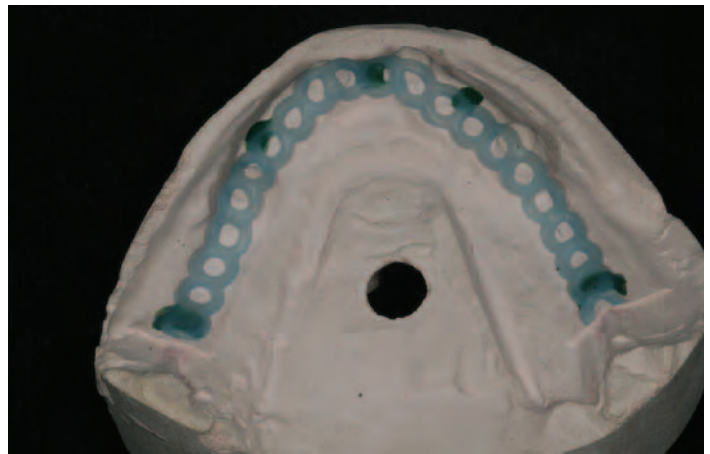


Figure 7 — Waxed framework for support

three versions: implant abutment, prefabricated titanium threaded for all CAD/CAM or cast bar connections with a standard 2mm thread and castable. For this case prefabricated abutments were used.

The denture tooth set-up (Fig. 4) was verified that the bite was right on the money. The next step was to send the case out for the milled bar fabrication. Before it was sent out a putty matrix was made of the waxed set-up. The matrix and the set-up was sent along with the case. When the set-up was taken off the model and the matrix was put in place, we were confident that we had enough room for a nicely designed bar with OT Equator attachments.

The bar was milled with four 2mm threads to accept the Rhein 83 OT Equator abutments and was made in accordance with the specific implants placed (Figs. 5 and 6). After the bar was received back at the lab, the next step was to make an internal cast metal framework. A refractory model was made and a wax-up was completed to fit over the milled bar (Fig. 7). After the framework was cast and finished (Fig. 8), another wax denture set-up with Equator housings and retentive caps in place was fabricated (Fig. 9). The abutments were screwed into place and the housings were processed to the mesh framework before the set-up was completed.

When selecting denture teeth for an

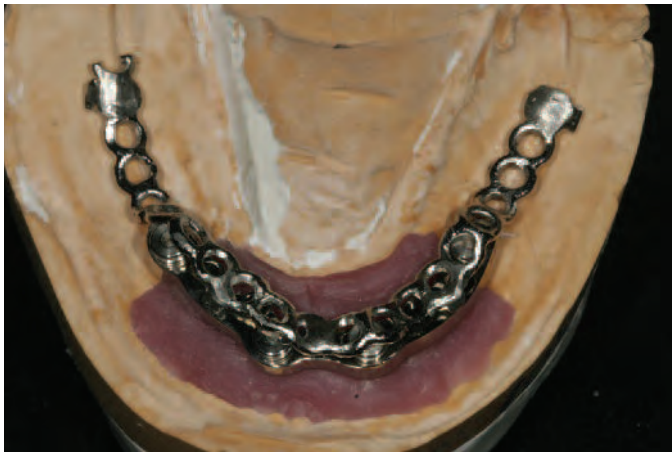

Figure 8 — Cast and finished support framework

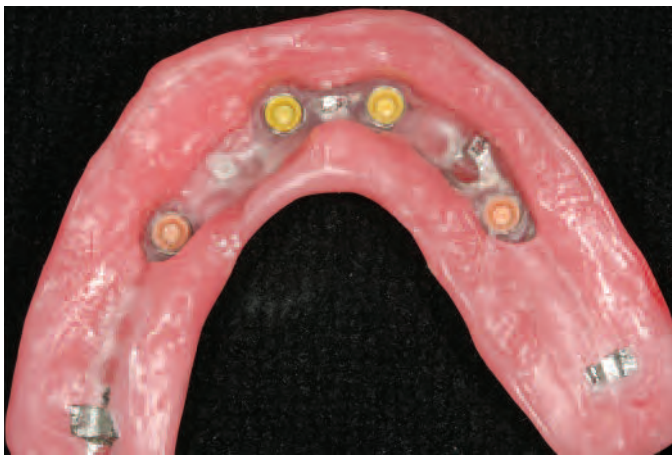

Figure 9 — Rhein 83 housings processed to framework for try-in

overdenture case, many Denturists are not aware of the various choices there are. Esthetics, wear resistance, shade integrity and the proper occlusal scheme are of the utmost importance. The ultimate choice in denture teeth for an implant overdenture case is Vita teeth . The esthetic value and shade consistency alone surpasses any tooth on the market. My recommended choice for implant overdentures are Vitapan Plus anteriors and Lingiform posteriors. Both are available in Vita classic shades and 3D Master shades. Vitapan Plus are made with MRP (microfiller reinforced polyacrylic) which has the lowest abrasion levels of acrylic teeth.





Equator • Sphero Block • Strategy



800.393.7222
905.858.4022
www.nordenta.net

Call **NORDENTA** for
all your attachment
needs







We provide

- Technical support
- Case planning
- Training courses
- Technical manuals
- Instructional DVDs

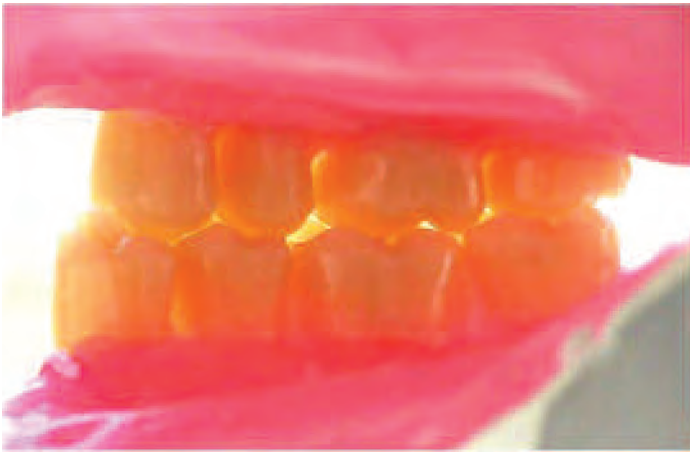

Figure 10 — Lingiform teeth in lingualized occlusion

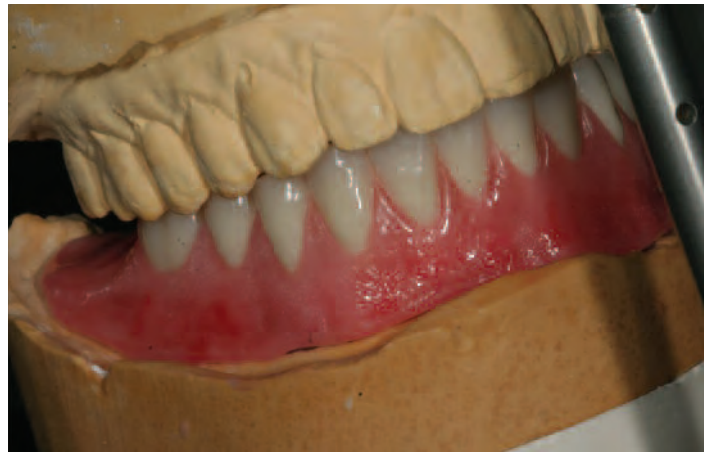

Figure 11 — Final waxed try-in

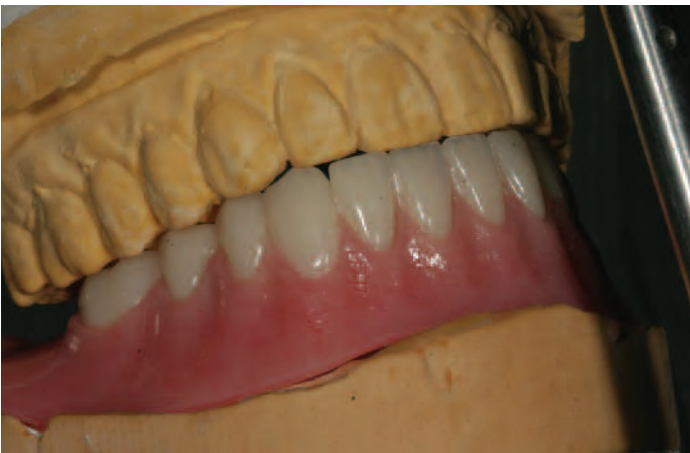

Figure 12 — Processed and finished implant overdenture

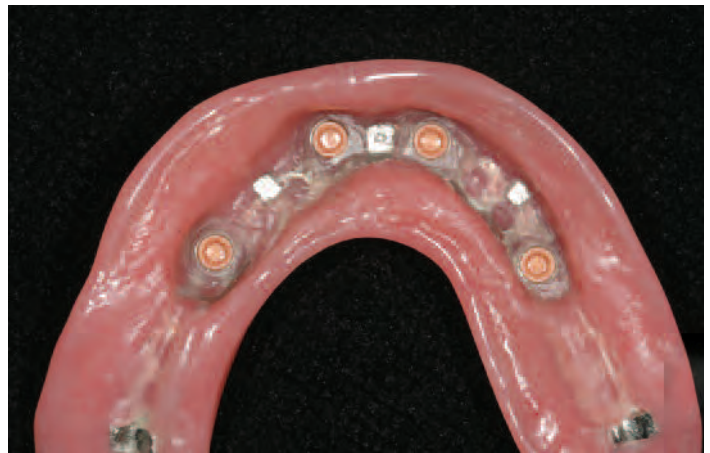

Figure 13 — Tissue side of processed denture showing Equator attachments

Lingiform posteriors are meant to be set in lingualized occlusion. Lingualized occlusion (Fig. 10) relieves any off axis stress on the implant and is the perfect occlusal scheme for implant overdentures.

The bar and waxed denture try-in were then sent to the Denturist to ensure everything fit and that the bite was correct (Fig. 11). So far all the necessary protocol had been followed on this particular case and when tried-in, it went perfectly. The case came back to the lab for a finish and we were now ready to process the case.

The case was then processed in high

impact denture acrylic. The combination of the mesh framework and high impact acrylic ensured the patient of a premium case where the fracturing of the denture base would not be a concern (Figs. 12 and 13).

Because all the protocol for an implant overdenture case was followed, this implant overdenture was a successful case. Case planning, following the correct protocol and utilizing the best materials including Rhein 83 OT Equator abutments and attachments and Vita teeth yielded to the ultimate goal - patient satisfaction. ■