

# Rehabilitation of edentulous arches

## The Double FiRe Bridge

**Authors:** Dr Marco Montanari, Claudio Sassatelli & Davide Nadalini, Italy

**Implantology allows the restoration** of missing or lost teeth by supporting fixed prostheses or anchoring removable prostheses. This has considerably expanded the possibilities of treatment and has allowed the patient to gain functional and psychological benefits and improved comfort, especially compared with conventional removable prostheses.<sup>1</sup> Every prosthetic rehabilitation aims to restore the stomatognathic apparatus, achieve satisfactory aesthetics—in harmony with the patient's face—and support soft tissue or compensate for loss.<sup>2-4</sup> In this situation, it is of great importance to choose the type of prosthesis (fixed or removable) and the means of realising it.<sup>5,6</sup>

The support of perioral tissue, lip mobility and the smile line are important parameters to take into account, because they affect the choice of the most appropriate prosthesis for the patient. Specifically, the relationship between the tooth profile and the volume of hard- and soft-tissue, which the prostheses must compensate for, gains particular significance in developing a treatment plan.<sup>2,5</sup> For this reason, a complete patient analysis, which is not limited to intra-oral examination, but includes extra-oral (frontal and profile) aspects, such as the smile line, perioral tissue, muscu-

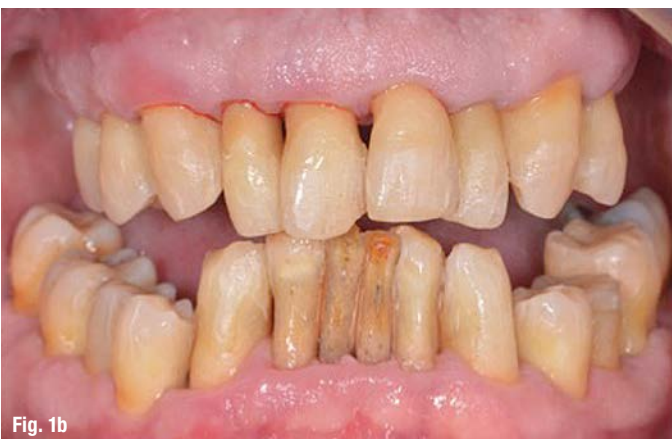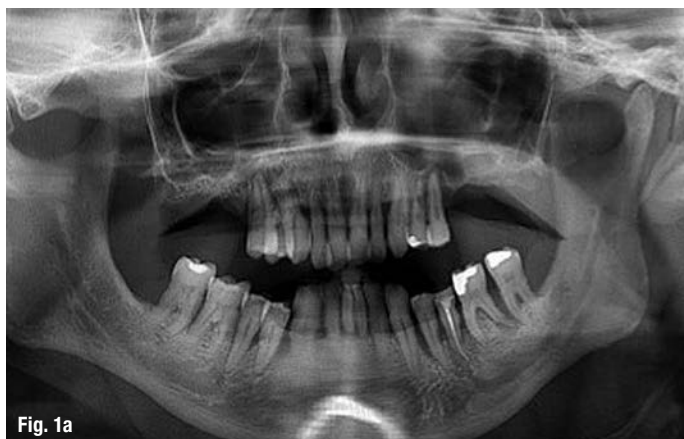loskeletal conformation, phonetics and hygiene habits, is of fundamental importance.

In cases of high crestal bone and gingival resorption, an implant-supported removable prosthesis is the obvious solution, since lost volumes can be supported by a prosthetic flange. This kind of prosthesis has the advantage of facilitating the patient's home oral hygiene, both of the framework and of the removable prosthesis itself, and gives the patient the feeling of wearing a fixed prosthesis.<sup>7</sup> However, in cases in which there is good maintenance of hard- and soft-tissue and the profile appears correct, with good support of perioral tissue, a fixed prosthesis appears to be the best option.<sup>2,5</sup>

Loss of hard tissue can be due to trauma, but it is more often due to periodontal problems that may lead to spontaneous tooth loss. Periodontitis is an infectious pathology that causes progressive resorption of the dental supporting structures (alveolar bone, periodontal ligament and root cementum), resulting in recession, deep periodontal pockets, tooth mobility, spontaneous gingival bleeding or bleeding on probing, and apical abscesses, ultimately resulting

**Figs. 1a & b:** a) Dental panoramic tomogram showing periodontal problems on both arches.

b) Intraoral photograph showing signs of generalised chronic periodontitis.



in loss of the teeth involved.<sup>8</sup> In periodontitis, the normal balance between bacterial plaque and the immune defence is altered and this leads to imperfect regulation of the inflammatory response, resulting in increased marginal periodontal destruction.<sup>9-11</sup>

When bone loss is consistent and makes it difficult or even impossible to place straight implants, it is possible to opt for tilted implants. The use of tilted implants allows the reduction of the distal cantilever and a better distribution of the forces.<sup>12</sup> In addition, the angle allows the use of longer implants, insertion of the implant into a better bone structure, and the preservation of noble anatomical structures, such as the mandible and the maxillary sinus.<sup>13,14</sup>

When a masticatory load is applied to a cantilever, compression forces are exerted on the distal implants and traction forces on the anterior implants. The magnitude of these forces is directly proportional to the length of the cantilever.<sup>15</sup> It has been shown that, with the insertion of four or six implants of the same length as the cantilever, forces acting on the most distal and anterior implants are comparable, allowing the simplification of the surgical procedures.<sup>15-17</sup> The implant angle also reduces the compression load in the connective area between abutment and bar and does not induce bone crest abnormalities compared with straight implants.<sup>15,18</sup>

In this article, the clinical situation of two male patients aged 66 and 67, respectively, are described, both of whom complained of mobility of residual teeth, periodontal problems, caries and poor aesthetics. The purpose of this article is to describe a new prosthetic protocol called DoubleFiRe (Fixed/Removable) Bridge, highlighting its functional, aesthetic and hygiene advantages. This protocol provides fixed rehabilitation of edentulous arches by the insertion of four tilted implants.

## Case 1

The patient showed signs of generalised chronic periodontitis that involved most teeth in both the upper and lower arches (Figs. 1a & b). Since the maxillary sinus was greatly pneumatised, there was increased difficulty of implant placement and proper prosthetic design. The extraoral examination found a convex, divergent profile with good masticatory muscle trophism. The perioral tissue was maintained and the nasolabial angle was around 90°. After careful diagnosis and clinical data collection, a treatment plan was developed that would involve a fixed maxillary implant prosthesis and a mandibular overdenture attached to the canine roots (#33 and #43), and two implants inserted into the interforaminal area (#32 and #42).

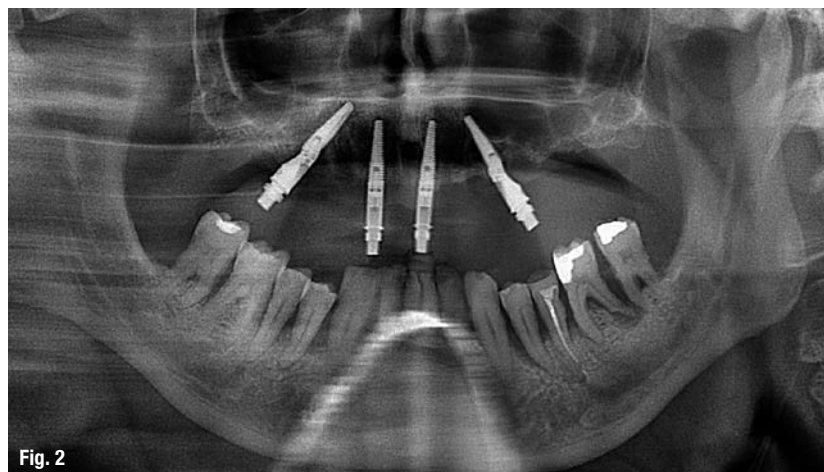


Fig. 2

**Fig. 2:** Post-op dental panoramic tomogram showing the positioning of the maxillary implants.

## Surgical protocol

The surgical protocol entailed anaesthesia at the level of the entire upper arch with articaine with 1:100,000 adrenaline, and antibacterial prophylaxis was administered in the form of 875 mg of amoxicillin plus 125 mg of clavulanic acid provided one hour before surgery and continued every 12 hours for six days. The teeth were extracted as carefully as possible not to damage the postextraction sites. Subsequently, a full-thickness flap was performed to achieve better visual access to the surgical area. Four exterior hexagonal implants (4 × 13 mm; Co-Axis 12 and 24°, Southern Implants) were placed in regions #15, 12, 21 and 24 (Fig. 2). Distal implants were angled to minimise the distal cantilever and to improve transmission of the masticatory load. The maxillary implants were placed at a torque reaching over 40 Ncm in order to follow an immediate loading protocol. At the end of the surgical procedure, suturing was performed using 4/0 silk.

## Prosthetic protocol

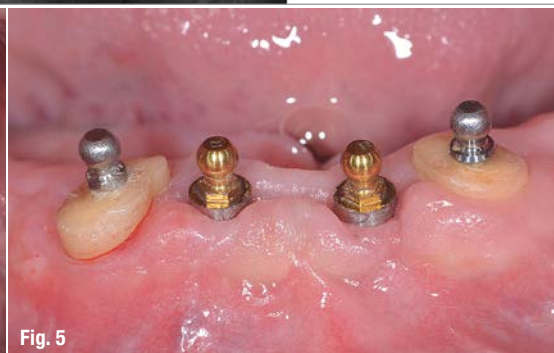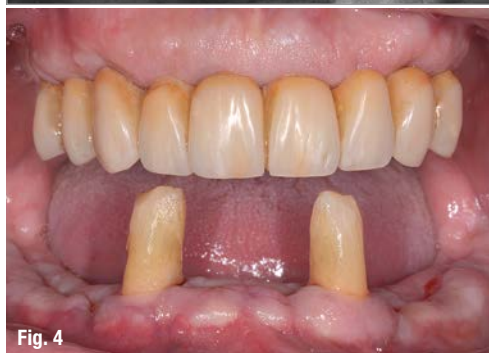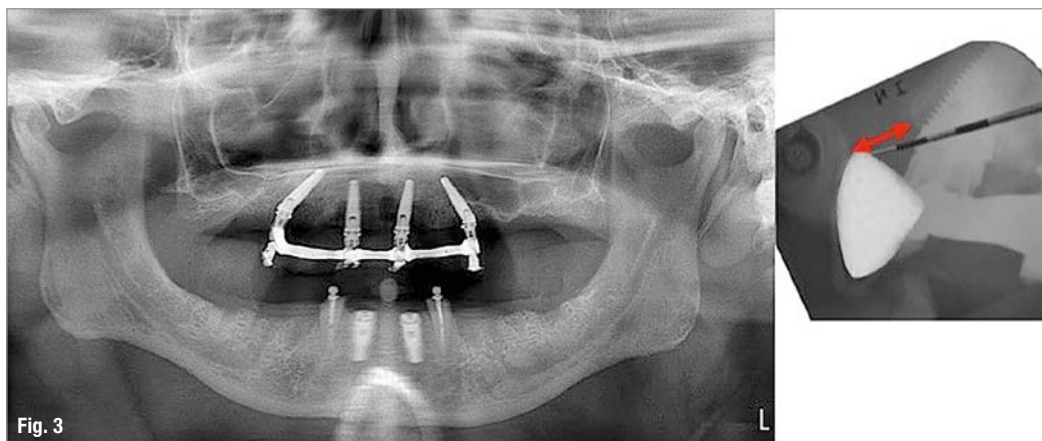
At the end of the operation, a polyether polyurethane impression (Impregum Penta, 3M ESPE) was taken, after bounding the impression copings with dual composite for greater precision. After 24 hours, the patient was provided with a fixed maxillary provisional prosthesis in acrylic resin with a cobalt-chromium internal reinforcement to have greater rigidity of the structure and better distribution of the load between the implants. The provisional was screwed directly to the fixture without the interposition of a multi-unit abutment owing to the geometry of the implants used. They have an angled prosthetic connection from the longitudinal axis, and this provides the possibility of correcting divergences. A lateral cephalometric radiograph confirmed the exact position of the prosthetic incisors from the alveolar crest, highlighting that the fixed rehabilitation was the best choice in this case (Fig. 3).

Owing to the marked angulation of the distal implants, it was possible to reduce the cantilever and

**Fig. 3:** Dental panoramic tomogram after seating of the temporary prosthesis.

**Fig. 4:** All teeth except for #33 and #43 were removed.

**Fig. 5:** Two implants were inserted in regions #32 and 42 and two spherical attachments were inserted to support and anchor a removable prosthesis.



avoid a regenerative maxillary sinus lift. Furthermore, owing to the peculiar connection of the Co-Axis implants, it was possible to handle the prostheses as if these implants were placed parallel. On the same day of the provisional prosthesis delivery, the mandibular teeth were extracted. Only #33 and #43 were preserved because they were found to be stable and to exhibit no caries or periodontal pathologies (Fig. 4).

A removable prosthesis, anchored with wire hooks to the mandibular canines, was delivered to the patient as a temporary prosthesis during osseointegration time and healing of the hard- and soft-tissue. After a few weeks, two cylindrical implants were inserted in regions #32 and 42 (PrimaConnex, Keystone Dental) and were left covered by the soft tissue for four months. During this period, the two mandibular canines were endodontically treated, sectioned at the gingival level to reduce the crown-root ratio, and two titanium pivots with normal-size spheres (Pivot Block, Rhein'83) were cemented in order to improve retention of the temporary prosthesis and, later, of the definitive prosthesis.

**Definitive prosthetic rehabilitation**

Four months after surgery, the mandibular implants were uncovered and, after evaluation of the cuff height, two Sphero Blocks with normal-size spheres (Rhein'83) were screwed on (Fig. 5). At the upper arch level, four OT Equator attachments (Rhein'83; Fig. 6) were screwed on to the implants, and an alginate impression was taken to produce the

individual impression trays. The individual impression tray was adequately edged with thermoplastic paste (ISO FUNCTIONAL, GC) and functionalised. Subsequently, polyether precision impressions (3M ESPE) were taken, using the appropriate pick-up impression coping for the maxillary OT Equator attachments and for the mandibular spheres.

After pouring of the pink silicone into the impressions to reproduce the gingival portions, the master model was poured in extra-hard plaster (Class IV). The dental technician then made a wax rim with a resin base in order to determine the maxillary relationship with the facial arch (Artex, Amann Girschbach). The correct height of the maxillary wax rim in the frontal area and the parallelism with the ala-tragal line (corresponding to the occlusal plane) and with the bi-pupillary plane were determined using the Fox plane (Candulor). The wax rim was held firmly by three retentive caps that were connected to the low-profile attachments in order to facilitate masticatory detection, median line recording, smile show and canine position without using an adhesive paste. The rim, once returned to the laboratory, allowed setting up of the models in the articulator. After the references had been taken with the wax rims, the tooth set-up was done (Acry Plus EVO, Ruthinium). An aesthetic try-in was then done, paying particular attention to phonetics.

The assembly try-in provided a general appearance that harmonised well with the physiognomy of the



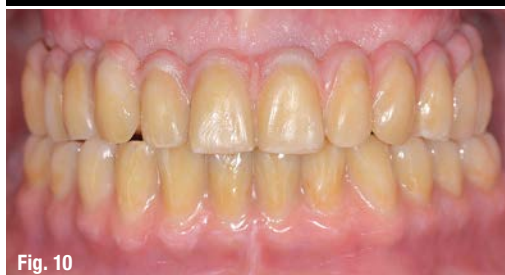
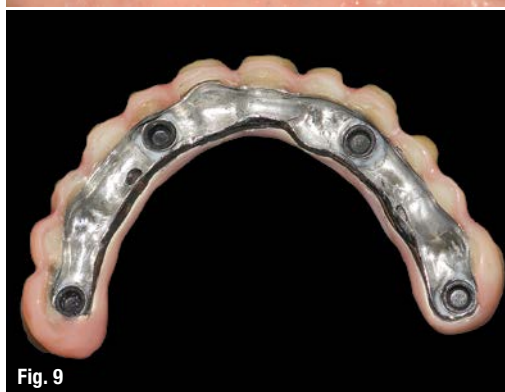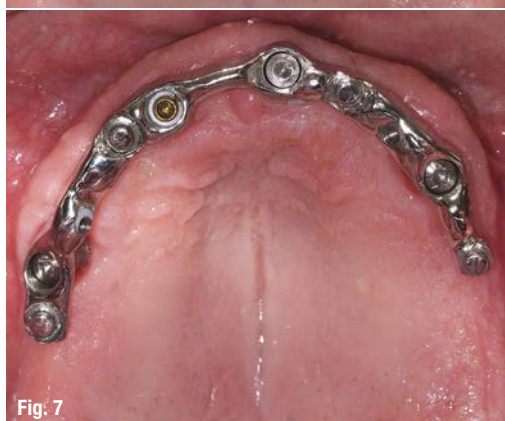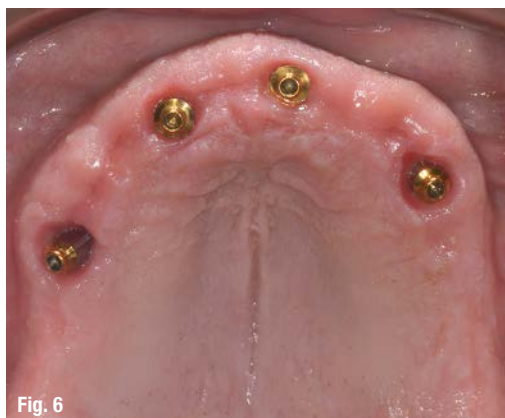**Fig. 6:** At the upper arch level, the cuff height was evaluated and the correct OT Equator low-profile attachments were screwed on.

**Fig. 7:** Primary bar anchored to low-profile OT Equator attachments by means of Elastic Seeger rings, whose function is to anchor the structure passively.

**Fig. 8:** The primary bar was assembled with castable material and subsequently cast in cobalt–chromium.

**Fig. 9:** Secondary structure anchored on the primary structure via OT Equator attachments and palatine screws.

**Fig. 10:** Delivery of the prostheses, which showed good harmonisation with the surrounding tissue and good aesthetics.



patient by providing a proper profile and aesthetics. After the assembly had been correctly done, the prosthetic volumes were evaluated while searching the available spaces for the reinforcement structure, both for the maxillary fixed prosthesis and the removable mandibular prosthesis. The Double FiRe Bridge protocol implemented in the present study entailed the construction of a primary bar anchored to low-profile OT Equator attachments using acetal rings called Elastic Seeger (Rhein'83), capable of blocking the whole structure by creating a functional and solid connection with guaranteed passivity.<sup>19</sup> Above each attachment, a cover screw was placed to increase the contact of the Elastic Seeger rings on the walls of the bar by improving the anchorage (Fig. 7).

On the occlusal surface, the bar had some OT Equator attachments that would allow a superstructure to be anchored if the clinician decided to turn the fixed prosthesis into a removable one. The primary bar, once cast, had two threads at the palatine level to which it was possible to attach the fixing screws for the secondary structure positioned above, thereby transforming the prosthesis into a fixed one (Fig. 8). The overlying secondary structure was precisely fitted on the primary bar and assembled according to the dentition tested during aesthetic and phonetic testing (Fig. 9). For the mandible, a cobalt–chromium reinforcement structure was cast, which had to be applied inside the containers on the spherical attachments for the retentive caps.

The definitive prosthesis was completed and characterised with colour stains to mimic the keratinised gingiva and dental discolorations to improve mimicry. In addition, the medial frenulum and the alveolar nerve were formed for a more natural look. The maxillary and mandibular prostheses were then delivered and showed proper harmony with the surrounding tissue and good aesthetics provided both by the features of the teeth and flange and by the absence of occlusal access holes for the screws, commonly present in fixed screw-retained prostheses (Fig. 10). The final dental panoramic tomogram showed correct fitting of the prostheses, correct adjustment of the maxillary bar and excellent maintenance of the peri-implant bone. The lateral cephalometric radiograph showed the close relationship between the base of the prosthetic central incisor and the implant neck to indicate how, in this case, fixed restoration was the best possible solution from an aesthetic and functional point of view (Figs. 11a & b).<sup>2,5</sup>

### Case 2

In the second case, a 67-year-old patient with multiple caries and periapical lesions of both maxillary and mandibular teeth was treated. The patient had a

skeletal Class III malocclusion with an inverse relationship of the arches, as evidenced in a lateral cephalometric radiograph (Fig. 12). After careful diagnosis and clinical data collection, it was decided on a treatment plan that included a removable implant-supported maxillary prosthesis and a fixed implant-supported mandibular prosthesis. On the day of surgery, anaesthesia was performed with articaine with 1:100,000 adrenaline, and all of the maxillary and mandibular teeth were extracted. In the maxilla, four tilted implants (M-Series [Internal Hex], Southern Implants) were inserted to reduce the distal cantilever and improve distribution of the masticatory load. Four tilted implants (M-Series [Internal Hex], Co-Axis 12°) were inserted in the mandible, with the most distal ones having an angled connection of 12° from the main axis of the fixture (Fig. 13).

Since implant stability exceeded 50 Ncm, it was decided to apply an immediate loading protocol. Standard spherical attachments (Sphero Flex, Rhein'83) were screwed on the implants, and two temporary removable prostheses were provided. As a result of the divergence in the upper arch, the prosthesis was anchored only to the two most mesial fixtures, while in the lower arch, where Co-Axis implants were used, it was possible to anchor the prosthesis to all of the implants, because the connections, and consequently the spherical attachments, were almost parallel to each other.

### Definitive prosthetic rehabilitation

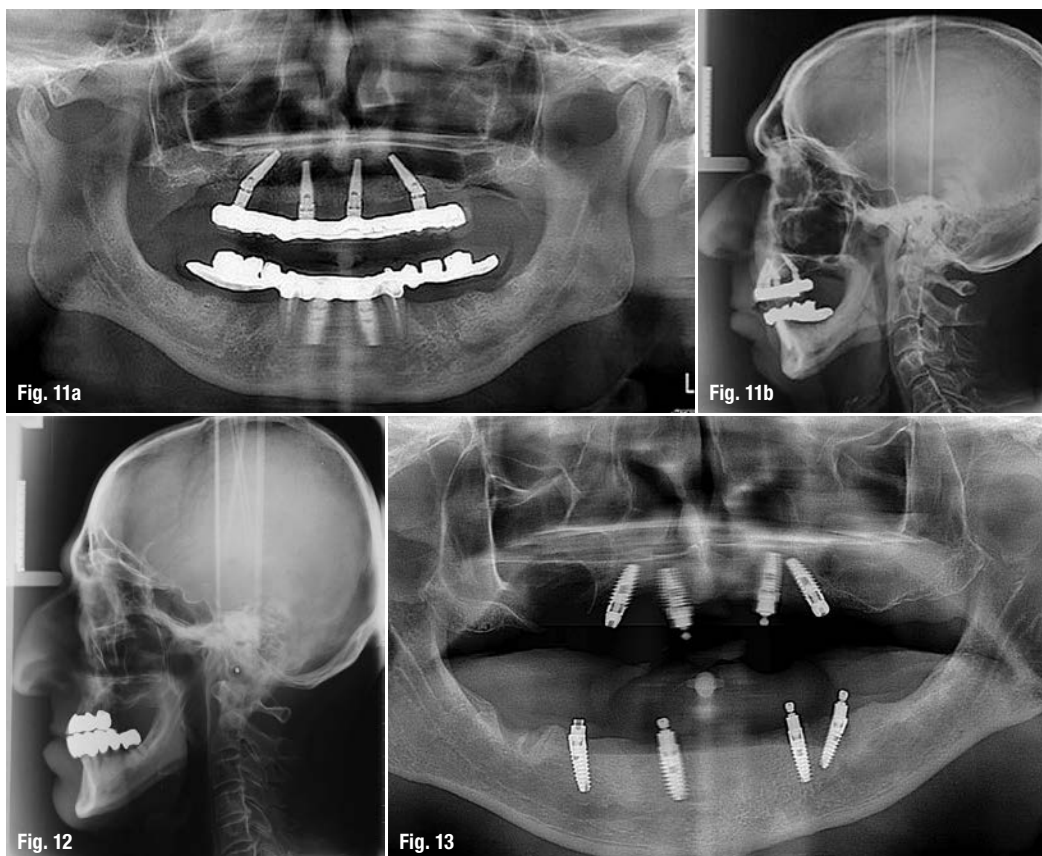
After four months, the maxillary distal implants were uncovered and OT Equator attachments were mounted on all fixtures (Fig. 14). Subsequently, alginate and polyether impressions were taken to complete the master model as described in the first case of this article. The maxillary relationship was recorded with the wax rim and the teeth were set up (Acry Plus EVO) to perform the aesthetic and phonetic tests. After the set-up had been checked, a cast bar with OT Equator attachments was designed to support the definitive removable maxillary prosthesis (Fig. 15). The bar was anchored to the OT Equator attachments by interposing Elastic Seeger rings, which guaranteed the passivity of the entire structure and the creation of a stable connection.<sup>19</sup>

A fixed prosthesis was realised in the mandible, consisting of a double structure (primary and secondary) anchored to the underlying implants, using OT Equator abutments and inserting Elastic Seeger rings for guaranteed passivity (Fig. 16). Four cast OT Equator attachments were located on the occlusal surface of the bar to allow a superstructure anchor should the clinician decide later to turn the fixed prosthesis into a removable one. On the lingual surface, however, there were two fixing screws, which enabled the prosthesis to be transformed into a fixed device by screwing on the overlying secondary structure, in which the teeth were present (Fig. 17). A radiograph

**Figs. 11a & b:** a) Final dental panoramic tomogram.  
b) Lateral cephalometric radiograph.

**Fig. 12:** Lateral cephalometric radiograph showing a skeletal Class III malocclusion with an inverse relationship between the arches. The poor support of the perioral soft tissue can be observed.

**Fig. 13:** Post-op dental panoramic tomogram showing the positioning of the maxillary implants, with the distal ones tilted to reduce the cantilever.



of the sagittal plane (Fig. 18) confirmed the position of the central incisor of the definitive prosthesis in relation to the alveolar ridge, highlighting that removable rehabilitation was the best choice in this case.

Owing to bone resorption in the maxilla, typical of patients with a skeletal Class III malocclusion, it was necessary to place the anterior teeth further in order to provide a Class I ratio. The final result (Fig. 19) confirmed the excellent aesthetics achieved in both the maxilla and the mandible and the harmonisation with the surrounding tissue. It can also be noted that choosing a higher and lower fixed-removable prosthesis associated with proper assembly made it possible to restore occlusion by creating an occlusal Class I. A fixed maxillary prosthesis would have resulted in the creation of a non-harmonious profile, owing to poor lip support and a retracted maxilla. Additionally, we would have created a very difficult area for the patient to clean; indeed, food residues would have easily accumulated in such an area. The insertion of a flange, however, allowed the restoration of a correct Class I profile with good support of perioral tissue and proper occlusion.

## Discussion

Loss of teeth and, consequently, of the supportive tissue necessitates restoration with a prosthesis to restore masticatory function and satisfactory aesthetics. Implantology, in this sense, has considerably expanded therapeutic possibilities by allowing fixed or removable prostheses based on the patient's need.<sup>1,20</sup> Since in the pathogenesis of periodontitis, there is poor hygiene control, it is important to educate the patient on following a good home hygiene routine and perhaps to propose a therapeutic solution for easy maintenance from a hygiene point of view.<sup>21</sup>

Preserving some roots and using them as anchorage allows the reduction of treatment costs, and provides a number of benefits. The maintenance of the periodontal ligament plays an important role in reducing maxillary resorption. In addition, the maintenance of proprioceptors and mechanoreceptors allows the masticatory system to safeguard the sensory feedback that regulates motor response. Sectioning the remaining teeth at the level of the gingival margins decreases the crown-root ratio, stabilises the tooth and improves the prognosis.<sup>22</sup>

Bone loss caused by periodontitis may not allow the insertion of implants in some sites. In order to overcome this disadvantage, a viable therapeutic possibility is the insertion of tilted implants as an alternative to complex regenerative surgeries, which are expensive and not immune to morbidity.<sup>23,24</sup> In fact, distal angled positioning allows the insertion of

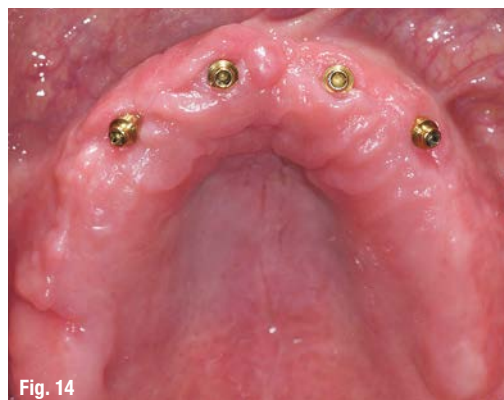

Fig. 14

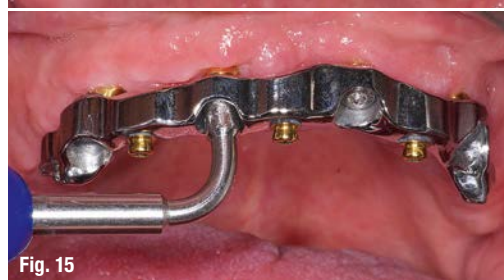

Fig. 15

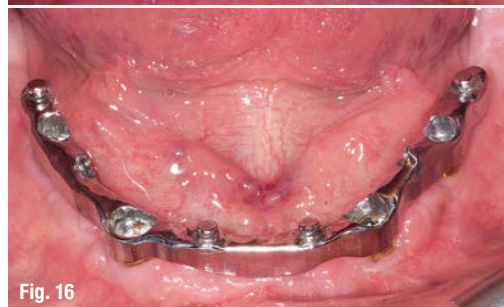

Fig. 16

**Fig. 14:** At the upper and lower arch level, peri-implant cuff height was evaluated and the low-profile OT Equator attachments were screwed on.

**Fig. 15:** Maxillary cast bar with OT Equator attachments to anchor the definitive removable maxillary prosthesis.

**Fig. 16:** Fixed prosthesis consisting of a double structure.

longer implants in areas with better bone quality, respects the noble structures (such as the inferior alveolar nerve or maxillary sinus) and reduces the cantilevers by better distributing occlusal forces.<sup>15,16</sup> The cantilever reduction is responsible for lower flexion of the load-bearing bar and less stress in the abutment-bar connective area.<sup>14</sup> In order to design the cantilever measurement, it is important to evaluate the distribution of the implants in the arches.

An anterior-posterior spread (AP spread) is defined as the distance between the line joining the distal edges of two rear implants with the centre of the more mesial implant. The AP spread is influenced by the shape of the arch: a triangular or elongated shape is associated with a favourable AP spread, while a square shape is unfavourable. A restoration on multiple implants to which a load is applied can be considered a Class I lever, in which the extension of the prosthesis from the last pillar represents the power arm, the last implant acts as a fulcrum, and the AP spread represents the strength arm. When a force acts on a cantilever zone, force transmission occurs in the underlying systems in two different ways: compression on the most distal implants and traction on the more mesial ones.<sup>25</sup>



The literature demonstrates how, by applying a load to a prosthetic arch supported by four or six implants, there are no stress differences at the fixtures if the more mesial and more distal implants are placed in the same respective locations.<sup>12,15</sup> Although tilted implants show a higher concentration of stress at the bone-implant interface, the literature shows that there are no statistically significant differences in peri-implant bone loss when compared with vertical implants.<sup>13,24</sup> In the present study, the insertion of tilted implants enabled implanting of the implant neck in a more distal position compared with an implant positioned vertically.

With Co-Axis implants, the angled connection from the longitudinal axis represents a valuable aid in correcting divergences and allowing more appropriate prosthetic positioning for the case. The ability to insert low-profile OT Equator attachments from the beginning without having to remove these during subsequent prosthetic phases is of remarkable biological benefit because it avoids damage to the epithelial ligament and the circumferential connective fibres around the implant neck. This achieves a biological seal and plays a key role in preventing and avoiding propagation of infections to the deep supportive tissue.<sup>26</sup>

When connecting the implants through a bar, passivity of the structure is a problem, since tension can be transmitted to the implants and lead, in particular, to incorrect fitting of the prosthesis and implant failure.<sup>27</sup> In order to achieve a bar with good passivity, several try-in tests with the patient are required, and corrections are not always easy. In the present study, the passivity of the bar was obtained by inserting Elastic Seeger rings between the bar and the OT Equator attachments. This device over-

comes the equator of the attachment and compensates for the space between the bar and the attachment itself, creating a solid connection with the guarantee of absolute passivity.<sup>19</sup>

The tolerance between the bar and OT Equator attachments is intended to compensate for the small inaccuracies that can arise between impression taking and plaster casting. The function of the screw is to improve the contact of the Elastic Seeger rings on the walls of the bar by improving its anchorage. Musculoskeletal analysis showed that the patients treated did not fall into the brachycephalic class in which the masticatory load is very high. This analysis appears to be very important during the prosthetic design because it is directly related to the occlusal load exerted on the implant-prosthesis structure.<sup>28</sup>

In Case 2, it was possible to perform immediate loading of the two maxillary anterior implants by inserting retentive caps with a gummy consistency and capable of anchoring the prosthesis to the spherical attachments and acting as a shock absorber. This allowed the distribution of the masticatory forces to the ridges, avoiding the overload of the two implants. In order to achieve this, however, the temporary prosthesis had a full palatal flange in order to have all the possible support on the palate, a non-compressible area, that provides support in the distribution of the occlusal load and improves retention and prosthetic stability.

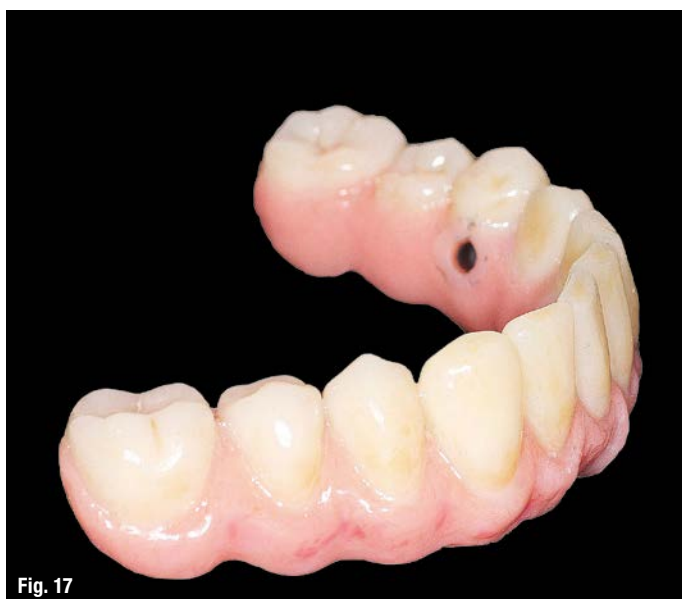### The Double FiRe Bridge protocol

The Double FiRe Bridge protocol implemented has several advantages:

- an aesthetic advantage, because there are no holes in the occlusal surface for screws;

**Fig. 17:** Lingual surface of the prosthesis; screw holes allowed the prosthesis to be transformed into a fixed device by screwing on the overlying structure bearing the teeth.

**Fig. 18:** The lateral cephalometric radiograph confirmed the position of the central incisor of the definitive prosthesis in relation to the alveolar ridge.



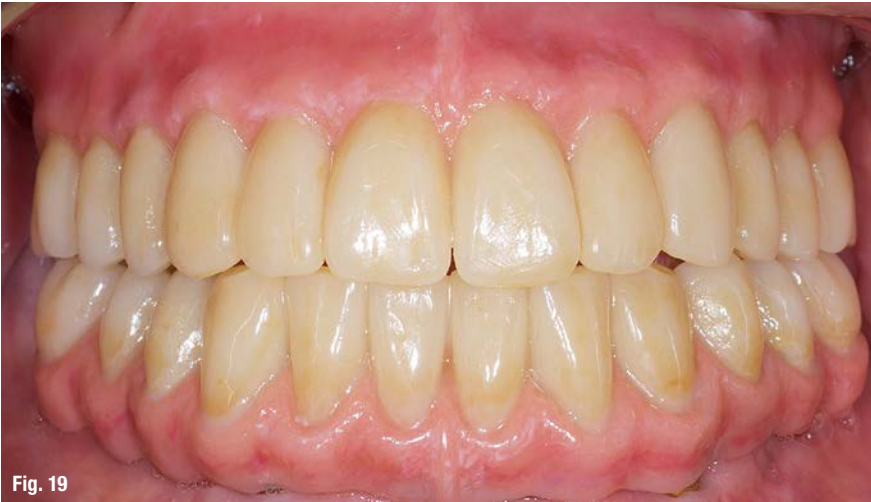

Fig. 19

Fig. 19: Final result.

- a functional advantage, because the clinician can decide at any time to switch from a fixed prosthesis to a removable one (or vice versa);
- a hygiene advantage, because the structure offers good maintenance and can be checked with greater simplicity.

By using the Double FiRe Bridge protocol, it was possible to combine aesthetics, structural passivity, hygiene and functionality in one prosthetic rehabilitation by solving some problems that may be encountered with conventional full-arch fixed restoration. Furthermore, the use of tilted implants allowed the reduction of the cantilever of the structure, despite the greatly pneumatized maxillary sinuses, and allowed improved transmission of the masticatory load. The characteristic of having an angled connection from the implant's main axis enabled the divergence to be solved immediately, giving the freedom to tilt the implants even more. In this way, it is possible to apply the cantilever protocol in a simpler and faster way without the interposition of additional prosthetic components.

In the Double FiRe Bridge protocol, the prosthesis consists of two structures (a primary structure and a secondary superstructure), solidly joined together owing to the insertion of two palatine locking screws. Following this workflow, it is possible to provide the patient with a fixed solution that can be converted into a removable device if necessary by simply removing the palatine/lingual fixing screws, if the patient's hygiene maintenance is poor or if better support of the soft perioral tissue is necessary.


This protocol is also helpful for the case in which the patient asks to first try a fixed prosthesis and then to eventually switch to a removable one (or vice versa). Having two structures locked together by lingual fixing screws also eliminates occlusal access holes, providing obvious aesthetic and structural advantages. In addition, the ability to quickly and easily remove the prosthesis during check-ups allows for more careful and accurate follow-up of the patient and therefore provides a longer-lasting rehabilitation through it being more easily inspected.

The protocol implemented in the present study proved to be a successful therapy and its association with the use of OT Equator and Elastic Seeger technology simplified the clinical and dental engineering procedures by reducing the treatment time and combining the benefits of a fixed prosthesis and a removable prosthesis within the same rehabilitation.

## contact

**Dr Marco Montanari**  
Viale Risorgimento, 244/A  
47121 Forlì, Italy  
Tel.: +39 0543 68910

Author details



Literature

